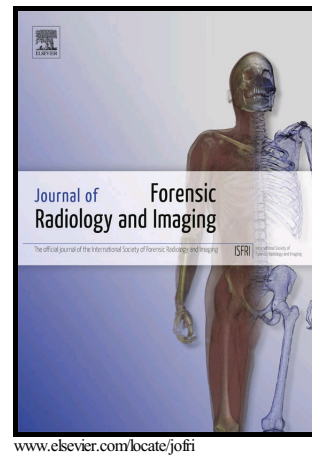


Author's Accepted Manuscript

3D reconstructions of a controlled bus bombing

Chiara Villa, Nikolaj Friis Hansen, Kamilla Maria Hansen, Hans Petter Hougen, Christina Jacobsen



PII: S2212-4780(17)30077-1
DOI: <https://doi.org/10.1016/j.jofri.2018.02.004>
Reference: JOFRI279

To appear in: *Journal of Forensic Radiology and Imaging*

Received date: 9 October 2017
Accepted date: 2 February 2018

Cite this article as: Chiara Villa, Nikolaj Friis Hansen, Kamilla Maria Hansen, Hans Petter Hougen and Christina Jacobsen, 3D reconstructions of a controlled bus bombing, *Journal of Forensic Radiology and Imaging*, <https://doi.org/10.1016/j.jofri.2018.02.004>

This is a PDF file of an unedited manuscript that has been accepted for publication. As a service to our customers we are providing this early version of the manuscript. The manuscript will undergo copyediting, typesetting, and review of the resulting galley proof before it is published in its final citable form. Please note that during the production process errors may be discovered which could affect the content, and all legal disclaimers that apply to the journal pertain.

3D reconstructions of a controlled bus bombing.

Chiara Villa^{a*}, Nikolaj Friis Hansen^b, Kamilla Maria Hansen^a, Hans Petter Hougen^a, Christina Jacobsen^a

^a Section of Forensic Pathology, Department of Forensic Medicine, Faculty of Health and Medical Sciences, University of Copenhagen, Frederik d. 5. 's Vej 11, DK-2100 Copenhagen, Denmark

^b Department of Radiology at Aarhus University Hospital, Palle Juul-Jensens Boulevard 99, DK-8200 Aarhus, Denmark

* **Corresponding author. E-mail address:** chiara.villa@sund.ku.dk

Abstract**Objectives**

to demonstrate the usefulness of 3D reconstructions to better understand the dynamic of a controlled bus bombing.

Materials and Methods:

3D models of the victims (pigs) were created from post-mortem CT scanning using Mimic software; 3D models of the crime scene (bus) were generated by means of photogrammetry and modelling techniques, using Photomodeler and 3Ds max software applications. Combinations and visualizations of the scene before and after the explosion were created using 3Ds max.

Results:

several 3D reconstructions of the scene before and after the explosion were re-created to better visualize the dynamic of the incident and the blast injuries. All the pigs suffered extensive blast injuries. The bomb pig and the green pig (adjacent to the detonation site) underwent traumatic amputation and destruction due to a combination of blast injuries. Primary blast injuries and secondary injuries were found in all the other pigs. Fractures both due to tertiary or combined blast injuries were found in all the pigs except the yellow one (far away from the detonation side). Three different "injury zones" could be identified based on the severity of the injuries of the pigs, as evaluated from autopsy and CT scanning.

Conclusion:

3D reconstructions give a clearer and more comprehensive view of the scene and the victims, allowing a better understanding of the entire scene. CT scanning has proved to be an important tool in evaluating blast injuries in dead victims.

1. Introduction

Terrorist attacks are increasing globally [1, 2]. Suicide bombings are the most devastating events in terms of wounded and killed victims in comparison with non-suicide explosions [2] and represent 5% of terrorist explosions worldwide [2]. Terrorist bombings have occurred for many years in the eastern world [3-5], in Ireland, [6, 7] and have also become more common in the western world (e.g. [8-15]).

Understanding the mechanism and spectrum of blast injury patterns in terrorist bombings is important not only to improve management and planning of hospital responses [16, 17], but also for forensic investigations [18, 19]. Important information can be obtained from the blast lesions reported by the victims, e.g. type of detonation, and location and distance of the victims from the detonation site [17, 18, 20]. Explosion-related injuries are categorized into four groups: primary, secondary, tertiary and quaternary blast injuries. Primary blast injuries result from the high-pressure wave and subsequent drop in pressure caused by the blast; these injuries mainly affect air-containing organs, such as ears, lungs, and the gastrointestinal tract resulting in haemorrhage, parenchymal injury with pneumothorax or air in the abdomen [21, 22]. Secondary blast injuries are caused by bomb fragments and flying debris (e.g. bolts and screws packed inside the bomb that act as projectiles) carried by the blast wind and can affect any body part generally associated with blunt or penetrating injuries. The combination of blast wave and blast wind can also cause traumatic amputation of body parts [4, 9, 17, 18]: the shockwave is capable of causing bone disruption and the subsequent blast wind completes the amputation [23, 24]. Other lesions, such as fractures and head injuries can also result from a combination of blast injuries [4, 9, 17, 18]. Tertiary blast injuries are produced by the displacement of the victims due to the blast wind against the surroundings or from structural collapses. Fractures and traumatic amputation to any body part are also a typical tertiary blast injuries. Quaternary blast injuries include the lesions produced by the fire and heat generated by the explosion, and typical injuries are flash burns, inhalation of toxins and dust, or asphyxiation. While not included in most of the literature, quinternary blast injuries are described as a delayed hyper-inflammatory response probably caused by chemicals involved in the blast [17]. For a more detailed review refer to e.g [9, 17, 18, 25, 26].

Several factors can increase the explosion's destructive potential and thus the severity of the blast injuries. The composition of the bomb play an important role; terrorists generally use improvised explosive devices (IED) which are less power than military explosives, but they are often equipped with additional objects such as bolts, screws or glass that increase the number and the severity of the injuries [9]. The environment also has a great impact: an explosion that occurs in a confined space is magnified by the reflection effects [20, 27, 28] increasing the mortality and

severity of the injuries [4, 17, 25]. Finally, the position of the victim also needs to be considered: the injuries and damages caused by the blast wave exponentially decreases with the distance to the detonation site in open space [28]. However, in the case of an explosion in a confined space, victims far from the explosion but adjacent to reflective surfaces can present similar lesions to those close to the detonation site [20, 27, 28].

Conventional radiology and CT scanning have been demonstrated to be invaluable tools in disaster victim identification [29-31]. Its usefulness has also been proven in case of terrorist attacks for assessing blast injuries and visualizing the presence of shrapnel or other foreign objects [10, 11, 32-34]. The CT information can also be 3D visualized and combined with 3D models of the crime scene to better understand the dynamic of the events [35, 36]. 3D crime scene reconstructions enable us to not only report the findings from the crime scene and victims in a more accurate and illustrative manner [37-39]; it has also been proven that 3D visualizations can help victims of terrorist suicide bomb attacks in the treatment of posttraumatic stress disorder [40].

The aim of this paper is to demonstrate the usefulness of 3D reconstructions to better understand the dynamics of a controlled bus bombing. The entire scene before and after the explosion was recreated by combining a 3D model of the scene (bus), obtained using photogrammetry and modeling techniques, and 3D models of the victims (pigs) generated from post-mortem CT scanning.

2. Materials and methods

2.1. Bus explosion

In November 2006, the Danish Police carried out an experiment in which a bomb of 8 kg was detonated within in a bus. The bomb was made of fertilizer and aluminium, a mixture known as ANAl or Ammonal (Ammonium Nitrate Aluminium) and has a relatively low detonation speed, about 3500 m/sec; TNT (Trinitrotoluene) has a detonation speed of 6900 m/sec. The bomb also contained some screws and bolts in order to act as “projectiles” upon detonation of the bomb.

Inside the bus, ten euthanized pigs were placed as terrorist and passengers to simulate and record injuries. One of the pigs (the “Bomb Pig”) carried the bomb placed in a backpack to simulate a suicide bomber. The Bomb Pig was positioned in the aisle by fastening its front legs to the upright metal bars on either side of the aisle with the backside and the backpack containing the bomb facing towards the front of the bus (Fig. 1b). The remaining nine pigs were individually color marked prior to the explosion to allow easy identification. Figure 1 shows the sketch of the individual positions of the pigs inside the bus (Fig. 1a). The explosion was videotaped from four different points of view outside the bus.

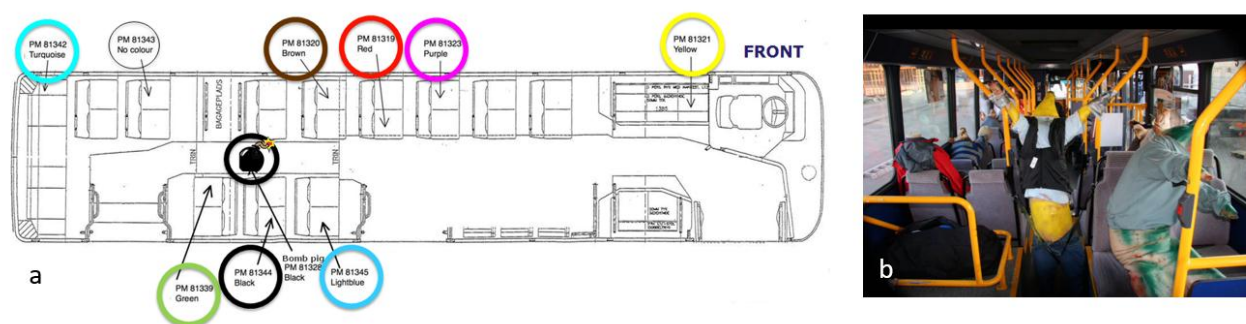


Figure 1: Inside view of the bus a) sketch of the bus with the positions of the pigs; b) a photograph (photo: N. F. Hansen)

2.2. 3D reconstructions

2.2.1 Victims (pigs)

The bodies of the pigs were recovered after the explosion and transported to the Department of Forensic Medicine at the University of Copenhagen for the analyses. Nine pigs, except the turquoise one, were CT scanned before the autopsy using a Siemens Volume Zoom 4 slice MSCT scanner. The whole-body scans were carried out in three parts: head, thorax and abdomen. The following scan settings were used: head (120 kV, 260 mAs, 3mm slice thickness, 2 or 1.3 mm slice

increment, reconstruction algorithm B20s), thorax (120 kV, 80 mAs, 3mm slice thickness, 2 or 1.5 mm slice increment, reconstruction algorithm B20s), and abdomen (120 kV, 80 mAs, mm slice thickness, 2 or 1.5 mm slice increment, reconstruction algorithm B20s). Three observers performed the reading of the CT-scans: a medical doctor, a consultant specialist in forensic pathology and a forensic anthropologist; all with several years of experience with forensic radiology. 3D reconstructions of the skin, bones, and metal objects were performed using Mimics software [41]. 3D models of the skin were generated using automatic segmentation applying a Hounsfield unit (HU) range from -260 to 3071. 3D models of the bones and metal objects were obtained using a HU range from 150 to 3071. The 3D models (bones, skin, and foreign objects) were exported as “.stl” files.

After scanning, all the pigs underwent a partial autopsy. A complete autopsy was not possible due to limitation of time and personal: only one medical doctor performed the autopsy of all the pigs. No opening of the skull and examination of the brain was carried out; no examination of the internal ear was conducted; and fractures were not systematically reported. A veterinarian was not present during the autopsy.

CT and autopsy findings were separately recorded and divided into external injuries, internal injuries/soft tissues and internal injuries/bones for each pig. The presence of debris or any foreign metal object was annotated. We also categorized the lesions based on type of blast injuries:

- Primary: blast lung and intestine rupture due to blast wave;
- Secondary: penetrating trauma due to debris and shrapnel propelled by the blast wind;
- Tertiary: penetrating, blunt trauma results from victims thrown by the blast wind against the surroundings (ground, walls, and objects) and lesions on the body area facing the bus walls;
- Combination injuries [9]: traumatic amputation, blunt lesions caused by direct effects of shock waves and blast wind and lesions on the body area facing the explosion.

CT and autopsy information are complementary. We did not compare the two methodologies.

3D models of the pigs prior to the explosion were created using the 3D model of a recently scanned pig. A whole-body CT scanning of this pig was performed using a Siemens Sensation definition with the following settings: 120kV, 300 mA, 3mm slice thickness, 3 mm slice increment and reconstruction algorithm B30f. 3D models of skin and bones was obtained using Mimics following the same procedure illustrated above.

2.2.2 *Crime scene*

A 3D reconstruction of the crime scene was carried out by means of photogrammetry and modelling techniques. A simplified 3D model of the bus was reconstructed using Photomodeler software [42] using the frames of four video cameras that recorded the explosion. Common points among the photographs were manually selected for orienting the pictures and obtaining a simplified sketch of the outside of the bus. A more detailed 3D model of the bus with internal and external surfaces was re-created combining the information from the Photomodeler model, the sketch, and photographs of the inside of the bus (figures 1 and 2) with a pre-designed 3D model of the bus [43]. 3Ds max [44] has been used to carry out the reconstructions. Accurate and precise measurements of the bus were not available at the time of the 3D reconstructions; the bus dimensions were arbitrarily set, using a Mercedes-Benz city bus as a reference model, one of the most used models in Denmark [45].

Several 3D visualizations of the scene before and after the explosion were made. 3D reconstructions of the scene and victims were used to better visualize the different blast injuries.

3. Results

3D model of the crime scene before the explosion with the pigs in the assigned seat can be seen in figures 3.

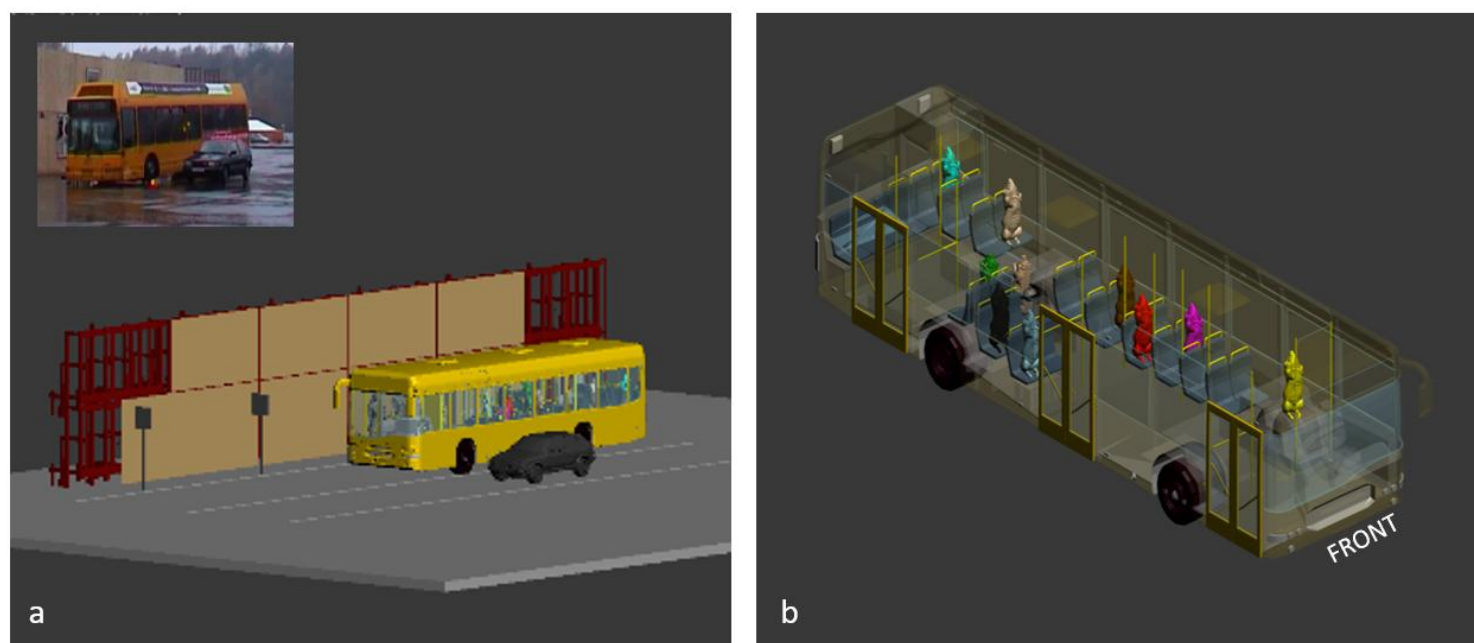


Fig 2: 3D visualization of the crime scene before the explosion: a) overview of the scene; b) inside view of the bus with the each pig in the assigned seat as reported in figure 1a.

The position of each pig relative to the detonation site, the position after the explosion and blast direction were documented and reported in the table 1. 3D visualizations have also been obtained (Fig. 3) for easy visualization of the information reported in table 1. A picture of the scene after the explosion was used to more accurately determine the trajectories of some pigs found outside the bus. (Fig 3)

Pigs	Position in relation to detonation site (DS)	Recovery position	Blast direction (relative to original position)
Bomb pig	DS	DS	
Green	Right side, aisle seat, facing backwards. "Behind" DS	Outside the bus	To the right and backwards
Black	Right side, window seat, adjacent to DS	Outside the bus	Directly to the right
Light blue	Right side, window seat, 1 row in front of DS	Outside the bus	Forward, to the right
Brown	Left side, window seat, 1 row in front of DS	Inside the bus	Forward
No colour	Left side, window seat, 2 rows behind DS	Outside the bus	Backwards, to the left
Red	Left side, aisle seat, 2 rows in front of DS	Inside the bus	Forward
Purple	Left side, window seat, 3 rows in front of DS	Inside the bus	Forward
Turquoise	Left side, window seat, 4 rows behind DS	Outside the bus	Backwards, to the left

Yellow	Left side, window seat, facing backwards approx. 7 rows in front of DS,	Inside the bus	Forward
--------	--	----------------	---------

Table 1: Position of the pigs before and after the explosion. DS= detonation site * as can be seen in the sketch of figure 1.



Fig. 3. 3D visualization of the information reported in table 3: a) with the photographs of the scene after explosion as background

The pigs were recovered and transported to the Department of Forensic Medicine, where they were CT scanned and underwent a partial autopsy. The detailed injuries are reported in tables 2 and 3. The precise location of the fractures are only reported in the CT scan findings (Table 2). CT and autopsy information are complementary.

Color/role	Body/body parts examined	External injuries	Internal injuries/soft tissues	Internal injuries/bones	Foreign bodies	Type of blast injuries
Bomb pig	Only pelvis and lower legs recovered	The skin of the pelvic area is severely lacerated, especially on the front. Skin on legs is intact, except minor lacerations	Remainders of intestines are visible.	Severely fractured pelvis and spine.	Debris and metal in soft tissues	Combination
Green	Entire body divided in two pieces. The body was transected from the right side of the neck/above the right shoulder downwards to the left.	The right side of the skin of head, neck and thorax is destroyed. The left side is intact but both superficial and penetrating lesions are present.	Internal organs are lacerated. Heart, liver, intestine and kidneys are probably present, as well as trachea and esophagus. Lungs are not identified.	Multiple fractures to the right mandibular ramus, the body of T1 and T2, 1-6 left ribs. The rest of the rib cage is missing. Only small pieces of ribs and the sternum are present. Fracture of the spinal process of L1 and right transverse process S1.	Debris on the surface, and two metal objects in the abdomen.	Combination
Black	Entire body	Laceration of external ears. Superficial skin lesion on the left side of the body; penetrating lesion on the left side around lumbar area.	Hemothorax left side; Collapse of the right lung; bilateral parenchymal laceration with blood accumulation; air in the abdomen.	Multiple fractures of the right maxilla and mandible (both left and right ramus), right ribs 2 to 12, left ribs 5 to 14, spinal process of T8 and T2, left transverse process of L2- L5, right transverse process L1	Debris and metal in soft tissue on the left side.	Primary, secondary, tertiary, combination
Light blue	Entire body	Lacerations of external ears, Penetrating injury in the left side of the abdomen and right gluteal region, perforation in the left lumbar region.	Bilateral collapse of the lungs and bilateral parenchymal laceration with blood accumulation.	Multiple fractures of both left and right maxillae, right ribs 5, 9-10, left 5 th rib, spinal process L3 and L4, transverse processes left side L1-L4	Small pieces of debris primarily on the right side of the body in the lumbar region. A screw in abdominal area, and another in right gluteal region.	Primary, secondary, tertiary, combination
Brown	Entire body	Deep lesion on the right side of the head and the thorax.	Both lungs perforated by a rib, collapse of the right lung, hemothorax left side and bilateral parenchymal laceration with blood accumulation; air in the abdomen.	Multiple fractures on the right side of the maxilla, fracture on the mandible, right side, Spinal process of vertebrae C5,C6, T1, T9-T12, L4, transverse process right L2- L4, right rib fracture 3-18 and 10, left rib 8-10, luxation of left ribs11-14: dislocated fracture left ribs 8-12	A screw in right upper jaw.	Primary, secondary, tertiary, combination
No color	Entire body	Laceration of lower jaw/chin and right side of neck. Deep lesion on the right side of thorax and one on the abdomen. Laceration on the right side of abdomen	Collapse of the right lung and bilateral parenchymal laceration with blood accumulation; air in the abdomen.	Multiple fractures to mandible both sides, nasal bone and maxilla both side. Right ribs 5-9.	Debris on the right side of the body and underside of head. Small pieces of debris on the abdominal area.	Primary, secondary, tertiary, combination
Red	Entire body	Deep lacerations in the right scapular region and on the back (T9-T10)	Collapse of the right lung; left sided hemothorax; bilateral parenchymal laceration with blood accumulation; lesion of medullar spine.	Multiple fractures on the right ribs 2-4 and 10; transverse process of T5-T9 and T12. Fractures of the body of T9-T10-T11.	A screw in the left side of T10.	Primary, secondary, combination
Purple	Entire body	Lacerations of external ears, superficial skin lesion on the left side of the head and frontally. Skin lesion right upper extremity.	Left sided hemothorax. bilateral parenchymal laceration with blood accumulation; air in the abdomen.	Fractures on the left ribs 8 and 9	Some small debris on the left side of the body.	Primary, secondary, tertiary
Turquoise	Entire body	<i>no CT scanning</i>	<i>no CT scanning</i>	<i>no CT scanning</i>	<i>no CT scanning</i>	
Yellow	Entire body	Superficial lesions on left shoulder region.	Left sided pneumothorax; bilateral parenchymal laceration with blood accumulation; air in the abdomen.	No fracture.	Small lesion? on the sacrum region externally	Primary, secondary

Table 2: CT scan findings

Color/role	Body/body parts examined	External injuries	Internal injuries/soft tissues	Internal injuries/bones	Foreign bodies	Type of blast injuries
Bomb pig	Only pelvis and lower legs	Severe lacerations of pelvic organs and muscles.		Severe fractures at the spine. Multiple pelvic fractures.	Gravel in soft tissue of lower body	Combination
Green	Entire body. Transected from right side of neck/above right shoulder downwards to the left	Several penetrating lesions, primarily on the right side.	Severe lacerations of upper body. Severed/transected spine and esophagus. Severe lacerations of thoracic and abdominal organs. Severed/transected spine.	Fracture of the mandible. Severed spine at mid thoracic part with fracture of vertebral body. Rib fractures. Severed spine at upper thoracic part with multiple fractures of right ribcage.	Small pieces of debris (upholstery etc. from bus) No identifiable parts from bomb. Rounded metal and pieces of glass/plastic superficially. Debris.	Combination
Black	Entire body	Deep skin lacerations of the left lower back. Several skin lesions in the face. No penetrating lesions into the body cavities.	Ruptured intestine.	Bilateral rib fractures.	Metal and upholstery material imbedded in deep skin lesions. No objects found in cavities.	Primary, secondary, tertiary, combination
Light blue	Entire body	Lacerations on the left side. Deep lacerations on the left front leg. Penetrating lesion of the left upper abdomen.	Abdominal penetrating injury.	Fractures of the upper thoracic ribs close to spine. Lumbar spinal processes.	Not found	Primary, secondary, tertiary, combination
Brown	Entire body	Multiple skin lesions on the right side. No penetrating lesions.	Lacerations of intestines and spleen.	Rib fractures on both sides. Multiple fractures on the right side of maxillary bone.	Screw at right upper jaw	Primary, secondary, tertiary, combination
No colour	Entire body	Multiple skin lesions on the right side. Deep lacerations on the lower jaw, right shoulder/upper thorax. Lacerations right outer and left inner thigh.	Normal	Mandibular fracture	None	Primary, secondary, tertiary, combination
Red	Entire body	Deep laceration on back, right outer thigh and left inner thigh.	Ruptured intestine	Mid spine (underlying back laceration)	Debris (upholstery) in laceration on back.	Primary, secondary, combination
Purple	Entire body	Superficial lesions on the right side	Ruptured intestine (multiple sites)	Rib fractures right side	None	Primary, secondary, tertiary
Turquoise	Entire body	Superficial lacerations left thigh and right neck	Puncture of right lung (related to rib fractures). Ruptured intestine. No penetrating lesions.	Rib fractures right side	None	
Yellow	Entire body	Superficial lesions on the upper body and head.	Ruptured intestine (multiple sites)	None	None	Primary, secondary

Table 3: Autopsy findings

Based on autopsy and CT information, three different “injury zones” could be identified based on the severity of the injury of the pigs (Figure 4):

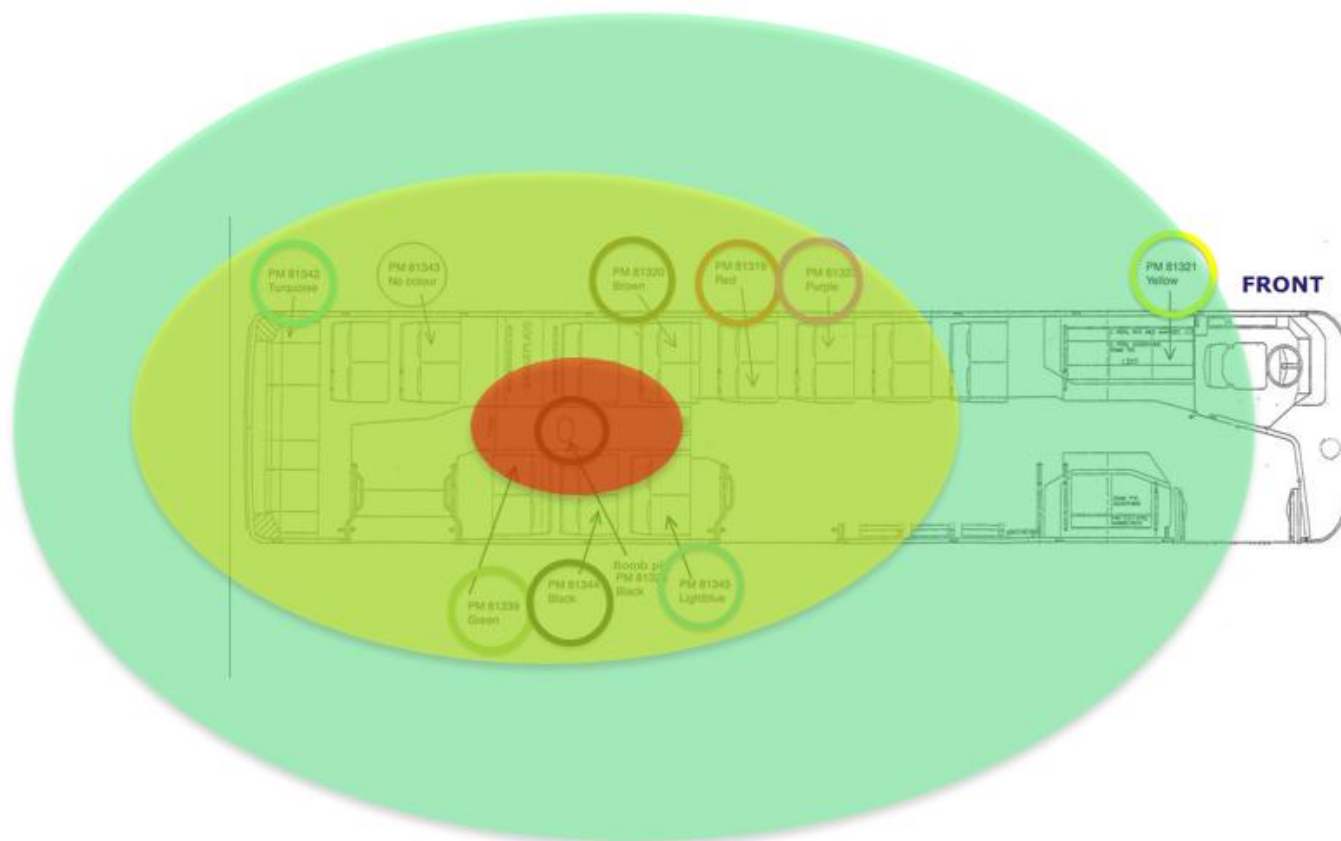


Figure 4: “injury zones”

- *Zone 1* corresponds to the area within one seat from the detonation side. The bomb pig and the green pig were situated in this zone. Both pigs suffered from severe injuries. The bomb pig (fig. 5a) was partially destroyed, only the pelvic area and lower extremities were found. The green pig was also severely lacerated with a transection going diagonally from the right side of the neck down towards the left upper part of the abdomen (Fig. 5b). Correspondingly, severe lacerations of thoracic and abdominal organs and transection of the spine was found internally. Foreign bodies were imbedded in the skin and inside both pigs. Injuries of the pigs probably resulted from a combined effect of the blast wave and the blast wind.

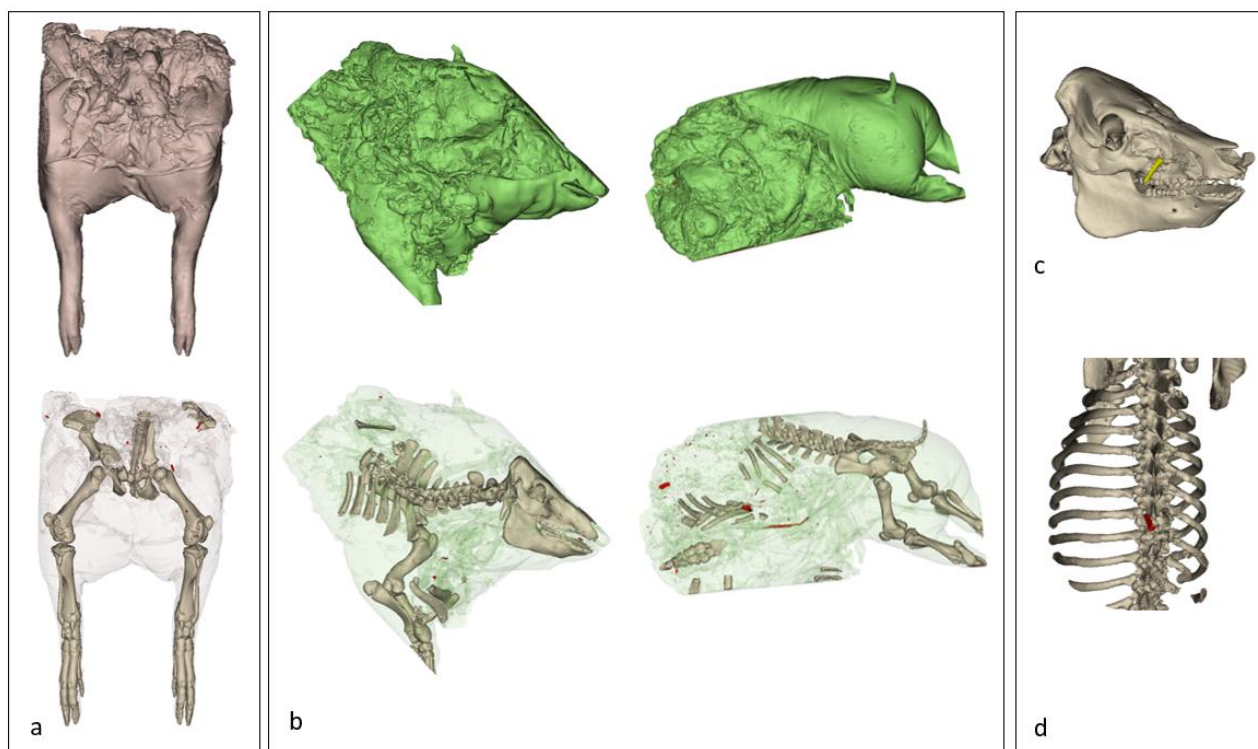


Fig 5. 3D reconstruction of pigs from CT: a) the bomb pig; b) the green pig. In red the metallic/debris fragments; c) The brown pig with a lesion on the right side of the face caused by a screw (in yellow); d) The red pig with a screw (in red) adjacent to the 10th thoracic vertebra.

- *Zone 2* corresponds to the area within two to four seats from the detonation site. Black, light blue and brown, no color, red and purple pigs were situated in this zone. Primary blast injuries can be seen in all the pigs in the form of hemothorax, collapse of the lungs, bilateral parenchymal laceration with blood accumulation and rupture of the intestine (except the no color pig). Secondary blast injuries were also documented: deep skin injuries on the side facing the detonation site in all pigs, except the purple one; superficial skin lesions and small pieces of debris imbedded in the skin in all the pigs. In addition, larger foreign bodies penetrated some of the pigs: in the blue pig, a screw was found in the abdominal area, and another one in the right gluteal region; in the brown pig, a screw was found at the right maxillary bone, corresponding to the maxillary fracture (fig 5c); and in the red pig a screw was found near the 10th thoracic vertebra (fig 5d). In addition, all the pigs had multiple fractures to the ribs and vertebrae and all (except the purple one) had fractures in the skull bones (mandible and maxillae).
- *Zone 3* corresponds to the area further than four seats from the detonation site. The yellow pig was situated in this zone. It had few superficial injuries and very limited small debris only posteriorly (secondary blast injuries). No fracture was observed.

To obtain an overview of the injuries of all the victims (except the turquoise pig since no CT scanning was performed) in the actual context, the 3D models obtained from post-mortem CT scanning were posed in the original position on the bus (Figure 6). The detonation site was indicated with a large red sphere. The bomb pig and the green pig sustained extensive injuries, including traumatic amputations most probably due to the combined effect of blast wave and blast wind.

Accepted manuscript




Fig 6: 3D visualization of the post-mortem 3D CT of the pigs: a) view from the back; b) view from the front




Fig 7: Primary blast injuries. Lesions to the lungs are indicated with a light blue sphere, while lesions to the intestine with a pink one.

All the pigs suffered of primary blast injuries (Figure 7). Lung injuries comprising parenchymal lesion with blood accumulation and pneumothorax (figure 8) were found in all the pigs, except the bomb and green pig and are indicated with a light blue sphere in the figure 7. Rupture of the intestines was found in all pigs except the pig with no color.

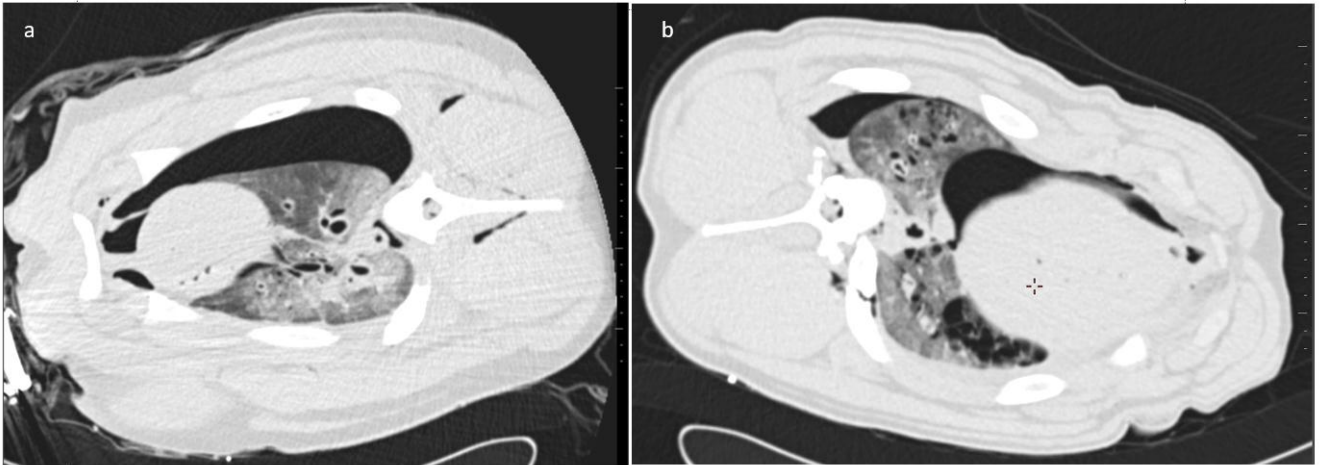


Fig 8: Primary blast lung injuries comprising parenchymal lesions with blood accumulation, pneumothorax and hemothorax: a) the light blue pig; b) the black pig presenting

Secondary blast injuries can be seen in figure 9. 3D reconstruction of the fragments from CT are colored in pink; external and internal lesions caused by debris/fragments moved by blast wind are indicated as yellow spheres. The fractures caused by penetrating objects, e.g. screws, are indicated with pink spheres. Most of the lesions are on the side facing the bomb.




Fig 9: Secondary blast injuries.

The single fractures resulting from tertiary blast injuries or combination blast injuries are marked with small red spheres and can be seen in figure 10. Larger red spheres were used to indicate the lesions in the bomb and green pigs. The 3D visualizations show that the pigs closer to the detonation site (black sphere) have most injuries. Interestingly, the purple pig (indicated with a white arrow) had only two fractured ribs; looking at the 3D models, it can be seen that it is partially protected by the red pig.




Fig 10: Fractures caused by tertiary blast injuries and the combination of different effects.

4. Discussion

Terrorist suicide attacks are an increasing phenomenon worldwide. A thorough documentation of both the scene and of the victims is important to understand the dynamic of such devastating events. In the recent years, the introduction of 3D technologies is changing the manner of documenting both the crime scene and victims. Surface scanners and photogrammetry have been proven very useful tools for 3D documentation of the scene and any other relevant evidence (building, vehicles, large and small objects) [24, 25]. 3D technologies are very accurate and allow a permanent documentation of the scene that can be used during the investigations as well as in court to better visualize all the evidences in one single environment [37, 38]. The experiment presented in this study was performed several years ago when the use of such technologies was not well known. However, we were able to recreate the scene using the photographs and the video even though it was not taken with the purpose of 3D documentation in mind. In our opinion, the 3D reconstructions allow for a more comprehensive overview of the scene than single photographs, sketches, and written documentation. A drawback in using old data is the fact that we did not have controlling measurement of the actual scene. Our reconstructions can therefore only be used for visualization, and new measurements can not be taken. Differently, the 3D models of the bodies obtained from CT scanning are measurable, including all of the lesions.

Documentation of the victims, both live and dead, can be generated using medical imaging technologies. Radiographic imaging, in particular CT scanning and X-ray, play a key role in the initial assessment of the patients in cases of terrorist attacks [33]. MR imaging is less used due to the risk of movement of metallic shrapnel [9]. Pulmonary blast injuries can be clearly observed on both X-ray and CT scanning. CT modality is more sensitive in detecting intestine rupture (primary blast injuries), foreign objects (secondary blast injuries) and fractures [46-48]. Post mortem CT scanning (PMCT) is an established technique in many forensic departments [49-54] and it is also important tool in DVI (Disaster Victim Identification [29-31, 55]. While numerous studies have described the blast injuries after terrorist attacks or military fatalities in clinical settings, little has been published about blast injuries from a medico-legal point of view [56-63]. Even fewer mentioned PMCT in such contexts [56, 57, 62].

Primary blast injuries were found in all pigs in our study. From PMCT analysis, we detected parenchymal lesions with blood accumulation and pneumothorax in most of the examinable pigs and hemothorax in four of them [21, 22]. Our results are in line with previous studies that have reported a high rate of lung injuries in confined space [1, 4, 56, 64, 65]. Finally, the rupture of the gastrointestinal tract has been reported but less commonly than lung and ear injuries [9, 64, 65]. We

found ruptures in the gastrointestinal tract in all of the pigs, except for the no color pig. These could only be evaluated during the autopsies. In contrast to those found in clinical settings, intestine rupture is difficult to diagnose on CT; diagnosis in the living is based on air in the peritoneal cavity. In case of post mortem images, the gas due to rupture of the intestine can be masked by gas formed due to decomposition [57].

Secondary blast injuries were observed in all the pigs. They varied from severe penetrating injuries to superficial penetration of debris in soft tissue. Most of the lesions were localized on the trunk. Their location correlates with the position of the bomb, situated on the back of the bomb pig. In comparison, the patients of the Boston marathon explosion showed most of the lesions in pelvis and lower extremities; in that case the bomb was positioned on the ground [9]. This shows the importance of a general overview of the location of the injuries in all the patients to better evaluate the position of the bomb at the time of the explosion. Fractures due to external objects packed in the bomb, such as screws and nails, were identified in three pigs. In addition, debris and any foreign objects were more easily identified on CT than at autopsy, as previously reported [8, 10, 11, 32, 34, 66]

Tertiary blast injuries were more difficult to recognize. They occur when the victims are thrown by the blast wind and impact upon the surroundings, or when they are hit by explosion-related structural collapse. Skeletal injuries, blunt and penetrating injuries are some of the common lesions. In our case, we were expecting to see such type of lesions on the body region facing the wall of the bus, but most of the fractures were on the side facing the explosion. In some situations, it may be difficult to establish which mechanism is responsible for which injury, and the injuries can be caused by a combination of mechanisms as previously reported [4, 10, 17, 18]. In addition, the correct interpretation of the skeletal fracture patterns resulting from blast injuries is difficult and still object of investigation [67-69]. In our victims, most of the fractures and the amputations are likely the result of a combination of shock wave and blast wind. This consideration was mainly possible after analyzing the 3D reconstructions. The contextualization of the victims in the actual scene allowed us to evaluate the injuries in a more comprehensive way, considering them in relation to the explosion site. As previously reported, it is important to evaluate the entire scene, environment and victims in all of its complexity and not limiting the observation to the single entities [35, 36, 70]. In such way, the dynamic of the event can be evaluated better.

The last consideration regards the victims of our experiment: the dead pigs. Previously, pigs have been used in experiments concerning blast trauma [67, 68, 71]. However, anatomic differences may have influenced the experiment and need to be mentioned. First, the limbs of pigs are shorter than in humans, and this could have influenced the rates of injuries such as traumatic

amputations and fractures of the long bones. In addition, the shape of the torso of the pig is also different: the torso of humans is more flat “front to back” compared to pigs who are more flat “side to side”. That could also have an effect on the rate of different injuries – especially if correlated with the angle at which the victim faces the bomb. The number of ribs in pigs are 15-16 pairs, increasing the number of fractures. Head morphology is also different: pigs have an elongated and curved skull with a thicker bone structure. Thus, the response to pressure, acceleration, and related head injuries in pigs are not necessarily the same as can be seen in humans [71]. The anatomy of the ear is also different [72, 73]: pigs have larger ears resulting in more damage to the outer part; pig’s auditory tube is cartilaginous throughout its length, while in humans it is part osseous, part cartilaginous; the air cell system is situated inferior to the tympanic cavity in pigs, while posteriorly in humans. In addition, the auditory tube is longer (around 10 cm) and for an examination special utensils are needed which were not available. Finally, the pigs were already dead at the time of the explosion, and thus the scenario is not completely realistic. Since the euthanized pigs have no circulation, some types of injuries will simply not be seen to the same degree as in living organisms.

To conclude, more systematic forensic reviews are needed as the recognition of the different pattern in blast injuries and their correlation with the underlying mechanism of injuries could help to develop strategies for diagnosis and treatment [74], but also preventive measures to heighten protective constructions. The knowledge gained from this and similar studies may be used for elucidating future terror bombing incidents.

5. Conclusion

3D reconstructions give an illustrative and more comprehensive view of the entire scene (environment and victims). 3D visualization can be used to better evaluate the lesions and thus to better understand the dynamic of the event. CT scanning has been proven to be an important tool in evaluating blast injuries in dead victims. Lung injuries were easily identified in CT scanning. Contrarily, ruptures of the gastrointestinal tract are diagnosed more easily during autopsy. Debris and any foreign objects as well as fractures are easily localized on CT scans.

Acknowledgments

We would like to thank the former colleague, Dr. Klaus Poulsen, for performing CT scans, and all the technicians of the Department of Forensic Medicine for their great help during the autopsies.

We also thank Kim Lindhold from the Danish National Police, National Forensic Services for the invitation to the experiment, for the measurements, photo and videomaterial and Mads Skak Jensen from the Danish Emergency Management Agency for the information about explosive properties. CV was supported by the Danish foundation: “Rådet for Offerfonden”(Grant nr. 16-910-00034) Finally, we would like to thank the two anonymous reviewers for their helpful suggestions and comments.

Accepted manuscript

Reference

- [1] Arnold JL, Halpern P, Tsai MC, Smithline H. Mass casualty terrorist bombings: a comparison of outcomes by bombing type. *Annals of emergency medicine*. 2004;43:263-73. 10.1016/S0196064403007236: 10.1016/S0196064403007236
- [2] Edwards DS, McMenemy L, Stapley SA, Patel HD, Clasper JC. 40 years of terrorist bombings - A meta-analysis of the casualty and injury profile. *Injury*. 2016;47:646-52. 10.1016/j.injury.2015.12.021: 10.1016/j.injury.2015.12.021
- [3] Hiss J, Kahana T. Suicide bombers in Israel. *The American journal of forensic medicine and pathology*. 1998;19:63-6
- [4] Leibovici D, Gofrit ON, Stein M, Shapira SC, Noga Y, Heruti RJ, et al. Blast injuries: bus versus open-air bombings--a comparative study of injuries in survivors of open-air versus confined-space explosions. *J Trauma*. 1996;41:1030-5
- [5] Raiter Y, Farfel A, Lehavi O, Goren OB, Shamiss A, Priel Z, et al. Mass casualty incident management, triage, injury distribution of casualties and rate of arrival of casualties at the hospitals: lessons from a suicide bomber attack in downtown Tel Aviv. *Emergency medicine journal : EMJ*. 2008;25:225-9. 10.1136/emj.2007.052399: 10.1136/emj.2007.052399
- [6] Rutherford WH. Experience in the accident and emergency department of the Royal Victoria Hospital with patients from civil disturbances in Belfast 1969-1972, with a review of disasters in the United Kingdom 1951-1971. *Injury*. 1973;4:189-99
- [7] Birchard K. Terrorist attack in Northern Ireland prompts major emergency action. *Lancet*. 1998;352:632. 10.1016/S0140-6736(05)79594-5: 10.1016/S0140-6736(05)79594-5
- [8] Brunner J, Singh AK, Rocha T, Havens J, Goralnick E, Sodickson A. Terrorist bombings: foreign bodies from the Boston Marathon bombing. *Seminars in ultrasound, CT, and MR*. 2015;36:68-72. 10.1053/j.sult.2014.10.006: 10.1053/j.sult.2014.10.006
- [9] Singh AK, Ditkofsky NG, York JD, Abujudeh HH, Avery LA, Brunner JF, et al. Blast Injuries: From Improvised Explosive Device Blasts to the Boston Marathon Bombing. *Radiographics*. 2016;36:295-307. 10.1148/rg.2016150114: 10.1148/rg.2016150114
- [10] Singh AK, Goralnick E, Velmahos G, Biddinger PD, Gates J, Sodickson A. Radiologic features of injuries from the Boston Marathon bombing at three hospitals. *AJR American journal of roentgenology*. 2014;203:235-9. 10.2214/ajr.14.12549: 10.2214/ajr.14.12549
- [11] Singh AK, Sodickson A, Abujudeh H. Imaging of abdominal and pelvic injuries from the Boston Marathon bombing. *Emerg Radiol*. 2016;23:35-9. 10.1007/s10140-015-1354-1: 10.1007/s10140-015-1354-1
- [12] Hare SS, Goddard I, Ward P, Naraghi A, Dick EA. The radiological management of bomb blast injury. *Clin Radiol*. 2007;62:1-9. 10.1016/j.crad.2006.09.013: 10.1016/j.crad.2006.09.013
- [13] Wong JM, Marsh D, Abu-Sitta G, Lau S, Mann HA, Nawabi DH, et al. Biological foreign body implantation in victims of the London July 7th suicide bombings. *J Trauma*. 2006;60:402-4. 10.1097/01.ta.0000203715.31280.65: 10.1097/01.ta.0000203715.31280.65
- [14] Gutierrez de Ceballos JP, Turegano Fuentes F, Perez Diaz D, Sanz Sanchez M, Martin Llorente C, Guerrero Sanz JE. Casualties treated at the closest hospital in the Madrid, March 11, terrorist bombings. *Critical care medicine*. 2005;33:S107-12
- [15] Marti M, Parron M, Baudraxler F, Royo A, Gomez Leon N, Alvarez-Sala R. Blast injuries from Madrid terrorist bombing attacks on March 11, 2004. *Emerg Radiol*. 2006;13:113-22. 10.1007/s10140-006-0534-4: 10.1007/s10140-006-0534-4
- [16] Kluger Y, Peleg K, Daniel-Aharonson L, Mayo A, Israeli Trauma G. The special injury pattern in terrorist bombings. *J Am Coll Surg*. 2004;199:875-9. 10.1016/j.jamcollsurg.2004.09.003: 10.1016/j.jamcollsurg.2004.09.003
- [17] Mathews ZR, Koefman A. Blast Injuries. *The Journal of emergency medicine*. 2015;49:573-87. 10.1016/j.jemermed.2015.03.013: 10.1016/j.jemermed.2015.03.013
- [18] Morley B, Leslie GD. Terrorist bombings: Motives, methods and patterns of injuries. *Australasian Emergency Nursing Journal*. 2007;10:5-12. 10.1016/j.aenj.2006.07.001: 10.1016/j.aenj.2006.07.001

- [19] Saukko P, Knight B. Gunshot and Explosion Deaths Knight's Forensic Pathology , Fourth Edition: CRC Press; 2016. p. 241-76.
- [20] Kluger Y. Bomb explosions in acts of terrorism--detonation, wound ballistics, triage and medical concerns. The Israel Medical Association journal : IMAJ. 2003;5:235-40
- [21] McDonald Johnston A, Ballard M. Primary Blast Lung Injury. Am J Respir Crit Care Med. 2015;191:1462-3. 10.1164/rccm.201501-0063IM: 10.1164/rccm.201501-0063IM
- [22] Scott TE, Kirkman E, Haque M, Gibb IE, Mahoney P, Hardman JG. Primary blast lung injury - a review. Br J Anaesth. 2017;118:311-6. 10.1093/bja/aew385: 10.1093/bja/aew385
- [23] Patel HD, Dryden S, Gupta A, Ang SC. Pattern and mechanism of traumatic limb amputations after explosive blast: experience from the 07/07/05 London terrorist bombings. J Trauma Acute Care Surg. 2012;73:276-81. 10.1097/TA.0b013e318256dd80: 10.1097/TA.0b013e318256dd80
- [24] Hull JB. Traumatic amputation by explosive blast: pattern of injury in survivors. Br J Surg. 1992;79:1303-6
- [25] Ciraulo DL, Frykberg ER. The surgeon and acts of civilian terrorism: blast injuries. J Am Coll Surg. 2006;203:942-50. 10.1016/j.jamcollsurg.2006.07.028: 10.1016/j.jamcollsurg.2006.07.028
- [26] Champion HR, Holcomb JB, Young LA. Injuries from explosions: physics, biophysics, pathology, and required research focus. J Trauma. 2009;66:1468-77; discussion 77. 10.1097/TA.0b013e3181a27e7f: 10.1097/TA.0b013e3181a27e7f
- [27] Chaloner E. Blast injury in enclosed spaces. Bmj. 2005;331:119-20. 10.1136/bmj.331.7509.119: 10.1136/bmj.331.7509.119
- [28] DePalma RG, Burris DG, Champion HR, Hodgson MJ. Blast injuries. The New England journal of medicine. 2005;352:1335-42. 10.1056/NEJMra042083: 10.1056/NEJMra042083
- [29] O'Donnell C, Iino M, Manshara K, Leditscke J, Woodford N. Contribution of postmortem multidetector CT scanning to identification of the deceased in a mass disaster: Experience gained from the 2009 Victorian bushfires. Forensic science international. 2011;205:15-28. <https://doi.org/10.1016/j.forsciint.2010.05.026>: <https://doi.org/10.1016/j.forsciint.2010.05.026>
- [30] Ruttly GN, Alminyah A, Cala A, Elliott D, Fowler D, Hofman P, et al. Use of Radiology in Disaster Victim Identification: Positional statement of the members of the Disaster Victim Identification working group of the International Society of Forensic Radiology and Imaging. Journal of Forensic Radiology and Imaging. 2013;1:218. 10.1016/j.jofri.2013.06.002: 10.1016/j.jofri.2013.06.002
- [31] Viner MD, Alminyah A, Apostol M, Brough A, Develter W, O'Donnell C, et al. Use of radiography and fluoroscopy in Disaster Victim Identification. Journal of Forensic Radiology and Imaging.3:141-5. 10.1016/j.jofri.2015.04.001: 10.1016/j.jofri.2015.04.001
- [32] Benjaminov O, Sklair-Levy M, Rivkind A, Cohen M, Bar-Tal G, Stein M. Role of radiology in evaluation of terror attack victims. AJR American journal of roentgenology. 2006;187:609-16. 10.2214/AJR.05.0591: 10.2214/AJR.05.0591
- [33] Shaham D, Sella T, Makori A, Appelbaum L, Rivkind AI, Bar-Ziv J. The role of radiology in terror injuries. The Israel Medical Association journal : IMAJ. 2002;4:564-7
- [34] Yazgan C, Aksu NM. Imaging features of blast injuries: experience from 2015 Ankara bombing in Turkey. The British journal of radiology. 2016;89:20160063. 10.1259/bjr.20160063: 10.1259/bjr.20160063
- [35] Buck U, Naether S, Braun M, Bolliger S, Friederich H, Jackowski C, et al. Application of 3D documentation and geometric reconstruction methods in traffic accident analysis: with high resolution surface scanning, radiological MSCT/MRI scanning and real data based animation. Forensic science international. 2007;170:20-8. 10.1016/j.forsciint.2006.08.024: 10.1016/j.forsciint.2006.08.024
- [36] Buck U, Naether S, Rass B, Jackowski C, Thali MJ. Accident or homicide - Virtual crime scene reconstruction using 3D methods. Forensic science international. 2013;225:75-84. 10.1016/j.forsciint.2012.05.015: 10.1016/j.forsciint.2012.05.015
- [37] Bolliger MJ, Buck U, Thali MJ, Bolliger SA. Reconstruction and 3D visualisation based on objective real 3D based documentation. Forensic Sci Med Pat. 2012;8:208-17. 10.1007/s12024-011-9288-8: 10.1007/s12024-011-9288-8

- [38] Errickson D, Thompson TJU, Rankin BWJ. The application of 3D visualization of osteological trauma for the courtroom: A critical review. *Journal of Forensic Radiology and Imaging*. 2014;2:132-7. <http://dx.doi.org/10.1016/j.jofri.2014.04.002>: <http://dx.doi.org/10.1016/j.jofri.2014.04.002>
- [39] Villa C, Olsen KB, Hansen SH. Virtual animation of victim-specific 3D models obtained from CT scans for forensic reconstructions: Living and dead subjects. *Forensic science international*. 2017. <http://dx.doi.org/10.1016/j.forsciint.2017.06.033>: <http://dx.doi.org/10.1016/j.forsciint.2017.06.033>
- [40] Josman N, Reisberg A, Weiss PL, Garcia-Palacios A, Hoffman HG. BusWorld: An Analog Pilot Test of a Virtual Environment Designed to Treat Posttraumatic Stress Disorder Originating from a Terrorist Suicide Bomb Attack. *Cyberpsychol Behav*. 2008;11:775-7. 10.1089/cpb.2008.0048: 10.1089/cpb.2008.0048
- [41] <http://www.materialise.com/en/medical/software/mimics>.
- [42] <http://www.photomodeler.com/index.html>.
- [43] <http://www.cadnav.com/3d-models/model-28464.html>.
- [44] <http://www.autodesk.com/products/3ds-max/overview>.
- [45] <http://myldretid.dk/billeder/vis.php?kategori=Mercedes-Benz>.
- [46] Aras MH, Miloglu O, Barutcuoglu C, Kantarci M, Ozcan E, Hararli A. Comparison of the sensitivity for detecting foreign bodies among conventional plain radiography, computed tomography and ultrasonography. *Dentomaxillofac Rad*. 2010;39:72-8. 10.1259/dmfr/68589458: 10.1259/dmfr/68589458
- [47] Meindl RS, Lovejoy CO, Mensforth RP, Walker RA. A revised method of age determination using the os pubis, with a review and tests of accuracy of other current methods of pubic symphyseal aging. *American journal of physical anthropology*. 1985;68:29-45. 10.1002/ajpa.1330680104: 10.1002/ajpa.1330680104
- [48] Jackes M. Building the bases for paleodemographic analysis: adult age determination. In: Katzenberg MA, Saunders SR, editors. *Biological anthropology of the human skeleton*. New York: Wiley-Liss; 2000. p. 417-66.
- [49] Burke MP. *Forensic Pathology of Fractures and Mechanisms of Injury: Postmortem CT Scanning*. New York: CRC Press. Taylor & Francis Group; 2012.
- [50] Ruddy GN, Morgan B, O'Donnell C, Leth PM, Thali M. Forensic institutes across the world place CT or MRI scanners or both into their mortuaries. *J Trauma*. 2008;65:493-4. 10.1097/TA.0b013e31817de420: 10.1097/TA.0b013e31817de420
- [51] Leth PM. The use of CT scanning in forensic autopsy. *Forensic science, medicine, and pathology*. 2007;3:65-9. 10.1385/FSMP:3:1:65: 10.1385/FSMP:3:1:65
- [52] Thali MJ. Virtopsy, a new imaging horizon in forensic pathology: Virtual autopsy by postmortem multislice computed tomography (MSCT) and magnetic resonance imaging (MRI) - a feasibility study. (vol 48, pg 386, 2003). *Journal of forensic sciences*. 2003;48:922-
- [53] Hayakawa M, Yamamoto S, Motani H, Yajima D, Sato Y, Iwase H. Does imaging technology overcome problems of conventional postmortem examination? A trial of computed tomography imaging for postmortem examination. *International journal of legal medicine*. 2006;120:24-6. 10.1007/s00414-005-0038-x: 10.1007/s00414-005-0038-x
- [54] Harcke HT, Bifano JA, Koeller KK. Forensic radiology: Response to the pentagon attack on September 11, 2001. *Radiology*. 2002;223:7-8. 10.1148/radiol.2231011850: 10.1148/radiol.2231011850
- [55] Morgan B, Alminyah A, Cala A, O' Donnell C, Elliott D, Gorincour G, et al. Use of post-mortem computed tomography in Disaster Victim Identification. Positional statement of the members of the Disaster Victim Identification working group of the International Society of Forensic Radiology and Imaging. *Journal of Forensic Radiology and Imaging*. 2014;2:114-6. 10.1016/j.jofri.2014.06.001: 10.1016/j.jofri.2014.06.001
- [56] Singleton JAG, Gibb IE, Hunt NCA, Bull AMJ, Clasper JC. Identifying future 'unexpected' survivors: a retrospective cohort study of fatal injury patterns in victims of improvised explosive devices. *Bmj Open*. 2013;3
- [57] Singleton JAG, Gibb IE, Bull AMJ, Mahoney PF, Clasper JC. Primary blast lung injury prevalence and fatal injuries from explosions: Insights from postmortem computed tomographic analysis of 121 improvised explosive device fatalities. *J Trauma Acute Care*. 2013;75:S269-S74. 10.1097/TA.0b013e318299d93e: 10.1097/TA.0b013e318299d93e

- [58] Rajs J, Moberg B, Olsson JE. Explosion-Related Deaths in Sweden - a Forensic-Pathological and Criminalistic Study. *Forensic science international*. 1987;34:1-15. Doi 10.1016/0379-0738(87)90079-X: Doi 10.1016/0379-0738(87)90079-X
- [59] Cooper GJ, Maynard RL, Cross NL, Hill JF. Casualties from Terrorist Bombings. *J Trauma*. 1983;23:955-67. Doi 10.1097/00005373-198311000-00001: Doi 10.1097/00005373-198311000-00001
- [60] Hull JB, Bowyer GW, Cooper GJ, Crane J. Pattern of Injury in Those Dying from Traumatic Amputation Caused by Bomb Blast. *Brit J Surg*. 1994;81:1132-5. DOI 10.1002/bjs.1800810815: DOI 10.1002/bjs.1800810815
- [61] Mellor SG. The Relationship of Blast Loading to Death and Injury from Explosion. *World J Surg*. 1992;16:893-8
- [62] Farkash U, Scope A, Lynn M, Kugel C, Maor R, Abargel A, et al. Preliminary experience with postmortem computed tomography in military penetrating trauma. *J Trauma*. 2000;48:303-8. Doi 10.1097/00005373-200002000-00018: Doi 10.1097/00005373-200002000-00018
- [63] Waterworth TA, Carr MJ. An analysis of the post-mortem findings in the 21 victims of the Birmingham pub bombings. *Injury*. 1975;7:89-95
- [64] Katz E, Ofek B, Adler J, Abramowitz HB, Krausz MM. Primary blast injury after a bomb explosion in a civilian bus. *Ann Surg*. 1989;209:484-8
- [65] Pizov R, Oppenheim-Eden A, Matot I, Weiss YG, Eidelman LA, Rivkind AI, et al. Blast lung injury from an explosion on a civilian bus. *Chest*. 1999;115:165-72
- [66] Sosna J, Sella T, Shaham D, Shapira SC, Rivkind A, Bloom AI, et al. Facing the New Threats of Terrorism: Radiologists' Perspectives Based on Experience in Israel. *Radiology*. 2005;237:28-36. 10.1148/radiol.2371040585: 10.1148/radiol.2371040585
- [67] Christensen AM, Smith VA. Rib butterfly fractures as a possible indicator of blast trauma. *Journal of forensic sciences*. 2013;58 Suppl 1:S15-9. 10.1111/1556-4029.12019: 10.1111/1556-4029.12019
- [68] Christensen AM, Smith VA, Ramos V, Shegogue C, Whitworth M. Primary and secondary skeletal blast trauma. *Journal of forensic sciences*. 2012;57:6-11. 10.1111/j.1556-4029.2011.01938.x: 10.1111/j.1556-4029.2011.01938.x
- [69] Dussault MC, Smith M, Osselton D. Blast injury and the human skeleton: an important emerging aspect of conflict-related trauma. *Journal of forensic sciences*. 2014;59:606-12. 10.1111/1556-4029.12361: 10.1111/1556-4029.12361
- [70] Thali MJ, Braun M, Buck U, Aghayev E, Jackowski C, Vock P, et al. VIRTopsy - Scientific documentation, reconstruction and animation in forensic: Individual and real 3D data based geo-metric approach including optical body/object surface and radiological CT/MRI scanning. *Journal of forensic sciences*. 2005;50:428-42
- [71] Shridharani JK, Wood GW, Panzer MB, Capehart BP, Nyein MK, Radovitzky RA, et al. Porcine Head Response to Blast. *Frontiers in Neurology*. 2012;3:70. 10.3389/fneur.2012.00070: 10.3389/fneur.2012.00070
- [72] Pracy JP, White A, Mustafa Y, Smith D, Perry ME. The comparative anatomy of the pig middle ear cavity: a model for middle ear inflammation in the human? *Journal of anatomy*. 1998;192:359-68. DOI 10.1046/j.1469-7580.1998.19230359.x: DOI 10.1046/j.1469-7580.1998.19230359.x
- [73] HaiJin Y, Weiwei G, Lei C, Na W, JiaNa L, LiLi R, et al. Microdissection of Miniature Pig Ear. *Journal of Otology*. 2013;8:91-6. [https://doi.org/10.1016/S1672-2930\(13\)50019-5](https://doi.org/10.1016/S1672-2930(13)50019-5): [https://doi.org/10.1016/S1672-2930\(13\)50019-5](https://doi.org/10.1016/S1672-2930(13)50019-5)
- [74] Aharonson-Daniel L, Almog G, Bahouth H, Feigenberg Z, Kluger Y, Peleg K, et al. Mass Casualty Events-Suicide Bombing: The Israeli Perspective In: Elsayed NM, Atkins JL, editors. *Explosion and Blast-Related Injuries Elsevier*; 2008. p. 307-35.

Highlights

- 3D reconstructions enable a comprehensive view of the scene and victims
- PMCT scanning is an important tool to evaluate blast injuries.
- Primary blast injuries to the lungs can be clearly evaluated in PMCT.
- Primary blast injuries to the intestine are better evaluable during autopsy.
- Debris, foreign objects and fractures can be clearly identified in PMCT.

Accepted manuscript